



ARP Account #

Hospital/Clinic

Veterinarian

Collection Date

ANIMAL
REFERENCE
PATHOLOGY

FELINE DERMATOHISTOPATHOLOGY FORM

OWNER NAME: _____ ANIMAL NAME: _____ ANIMAL AGE: _____

BREED: _____ COAT COLOR: _____ GENDER: M F M(N) F(S) PATIENT ID: _____ Biopsy Mini Biopsy (no microscopic description) Biopsy with Dermatology Consultation

Previous ARP accessions:

Send results (if not already on file) or duplicate results to:

Name: _____ Fax/Email: _____

SAMPLE SITE/LOCATION

OF SPECIMENS

HISTORY/LESION DESCRIPTION (Failure to provide appropriate information may result in delayed results)

Attach additional pages as necessary

ARE THE LESIONS PRURITIC? Yes NoARE THE LESIONS BILATERALLY SYMMETRIC? Yes NoHAVE DIGITAL IMAGES OF THE CLINICAL DISEASE BEEN SUBMITTED TO ARPRESULTS@ANIMALREFERENCEPATHOLOGY.COM? Yes No(Clinical images are very helpful with challenging dermatopathy cases. Please keep individual image file size at 300KB or less).

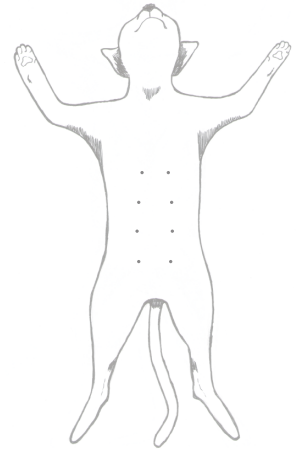
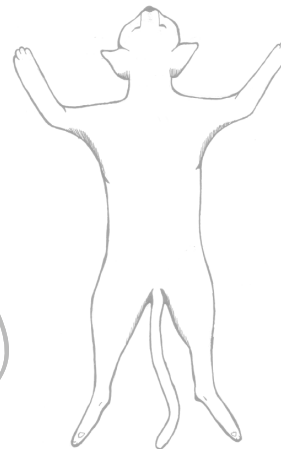
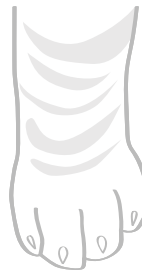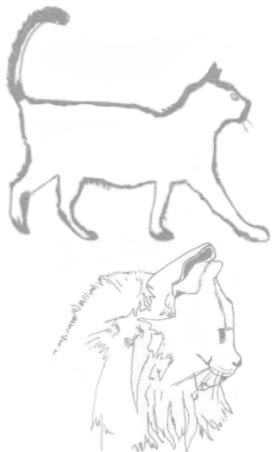DISTRIBUTION OF LESIONS: _____

PREVIOUS DIAGNOSTIC TESTS (cytology, skin scrapings, blood work, endocrine testing, culture and sensitivity, radiographs etc):PREVIOUS/CURRENT TREATMENT AND RESPONSE (antibiotics, steroids, antihistamines, topicals, etc):

PERTINENT HISTORY AND PHYSICAL EXAM FINDINGS:

 Alopecia Scales Hyperpigmentation Thickening Macules Pustules Ulcers Nodule/Mass
 Erythema Crusts Hypopigmentation Lichenification Papules Plaques Vesicles/Bullae Necrosis

WORKING CLINICAL DIAGNOSIS: _____



Illustrations by Kate Weed Lyman and Lindsay Thompson

WWW.ANIMALREFERENCEPATHOLOGY.COM

Advancing the art *and* science of veterinary medicine™

525 E 4500 S | Suite F200 | Salt Lake City, Utah 84107 | 800.426.2099 | arpreresults@animalreferencepathology.com